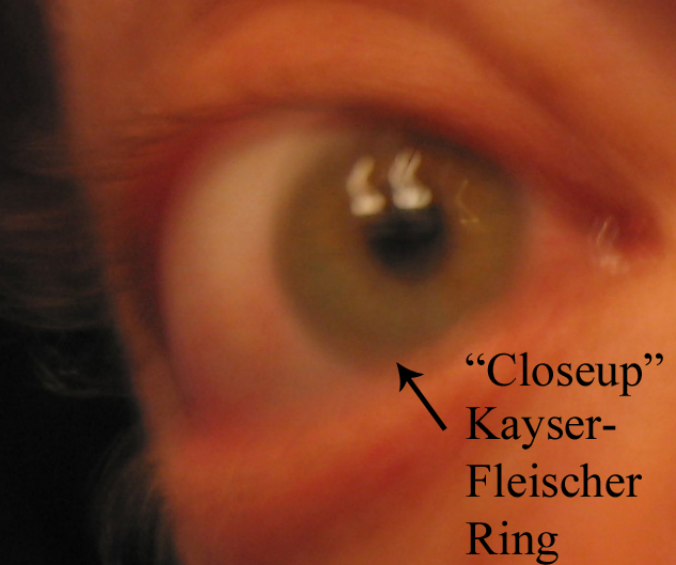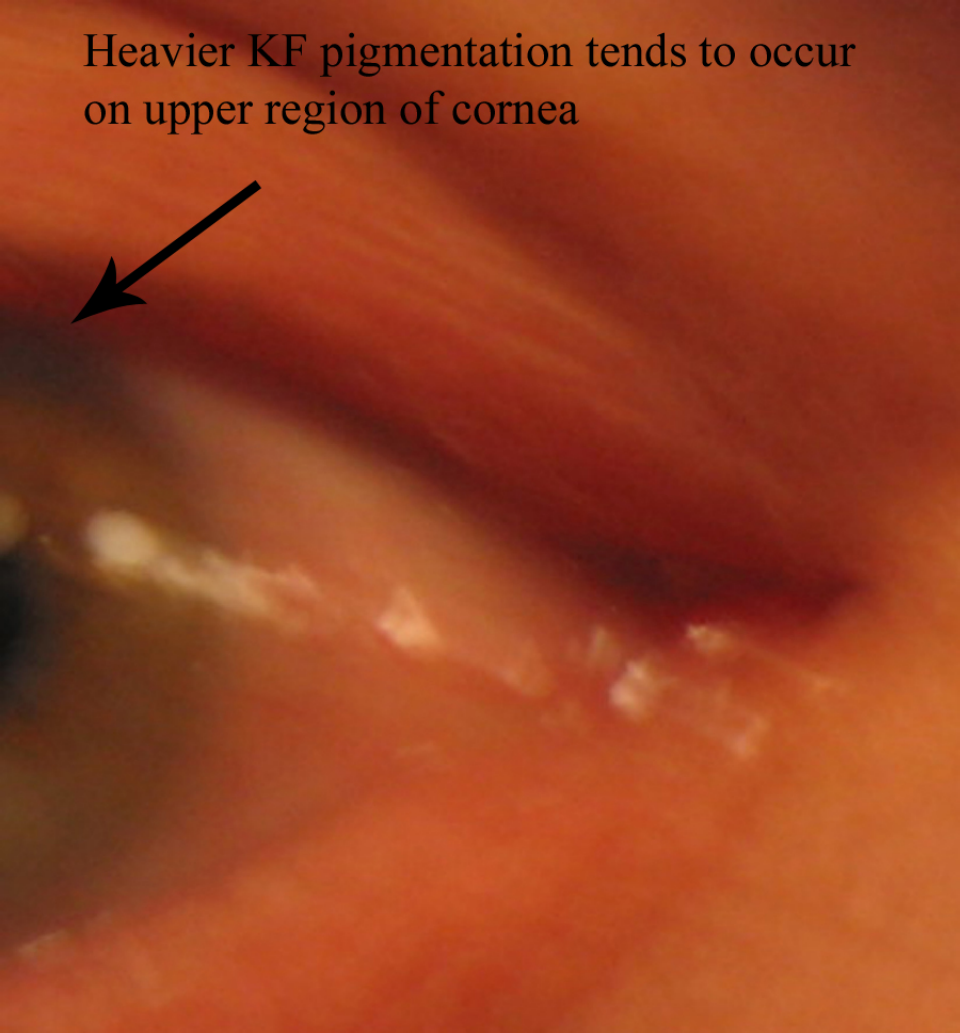
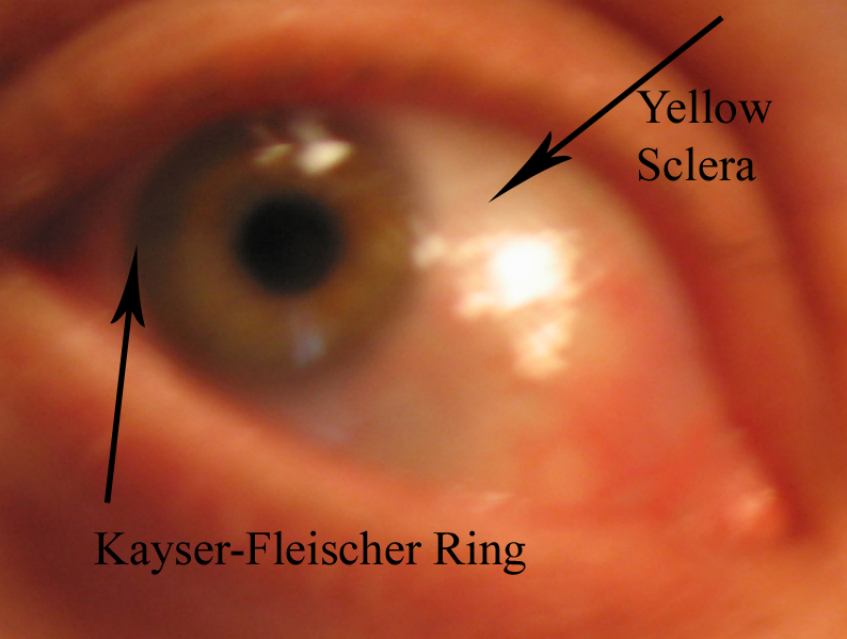


“Closeup”  
Kayser-  
Fleischer  
Ring

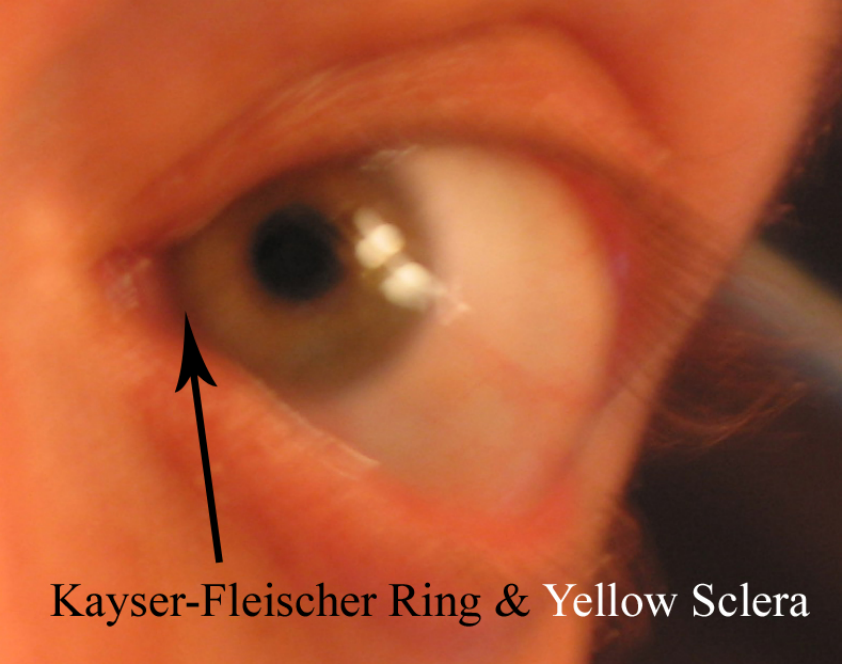
Heavier KF pigmentation tends to occur  
on upper region of cornea





Yellow  
Sclera

Kayser-Fleischer Ring



Kayser-Fleischer Ring & Yellow Sclera

With Kayser-Fleischer Rings (Wilson's associated) accumulation tends to be heaviest on upper region of cornea



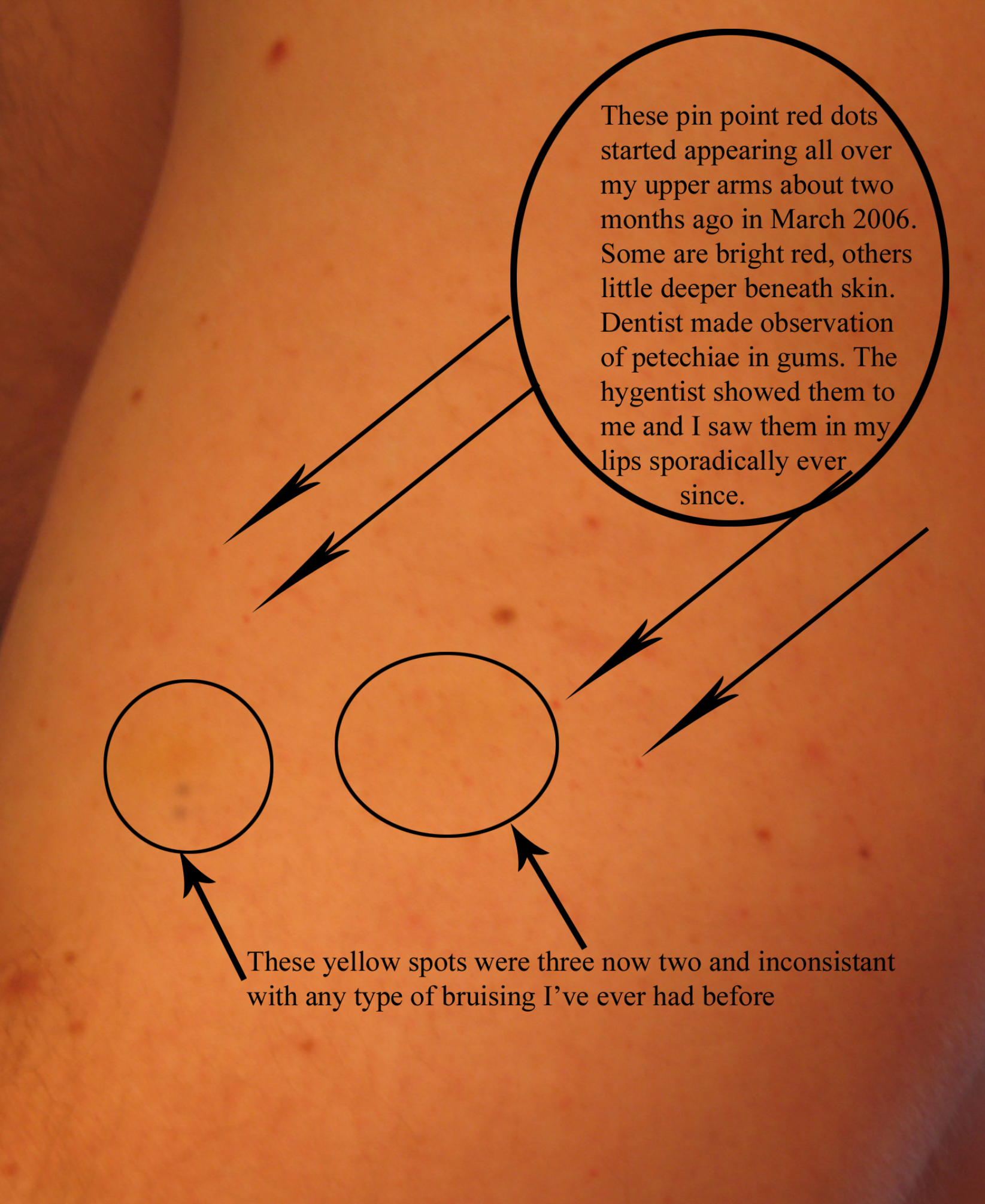
Yellow Sclera also noted - jaundice symptomatic of hepatic involvement Wilson's Disease





Yellowing Left Palm





These pin point red dots started appearing all over my upper arms about two months ago in March 2006. Some are bright red, others little deeper beneath skin. Dentist made observation of petechiae in gums. The hygentist showed them to me and I saw them in my lips sporadically ever since.

These yellow spots were three now two and inconsistant with any type of bruising I've ever had before