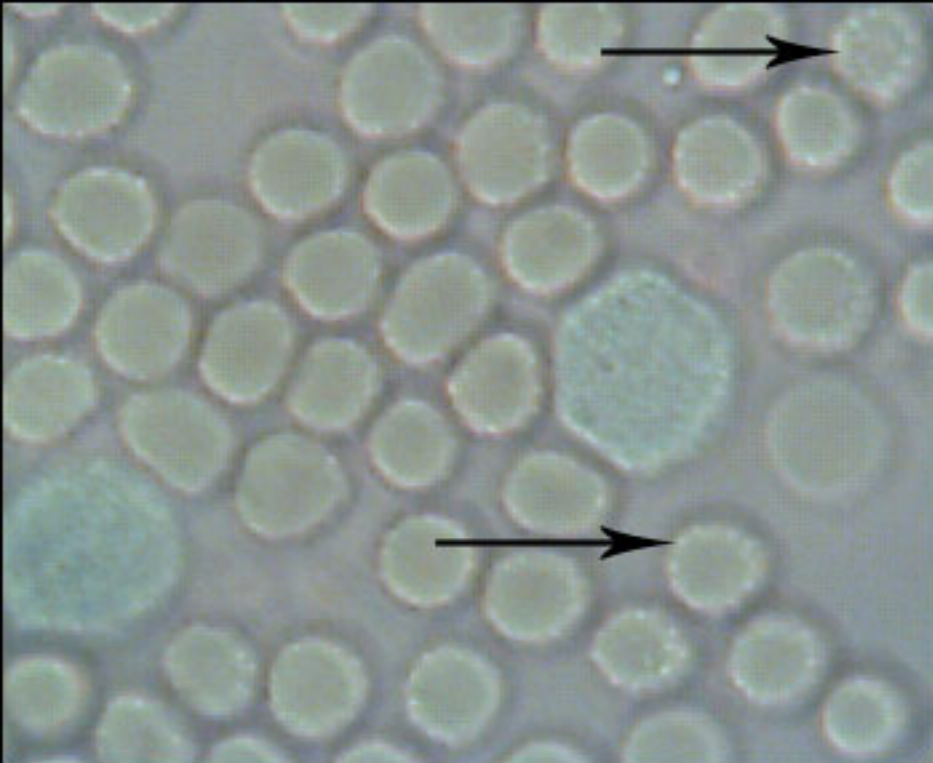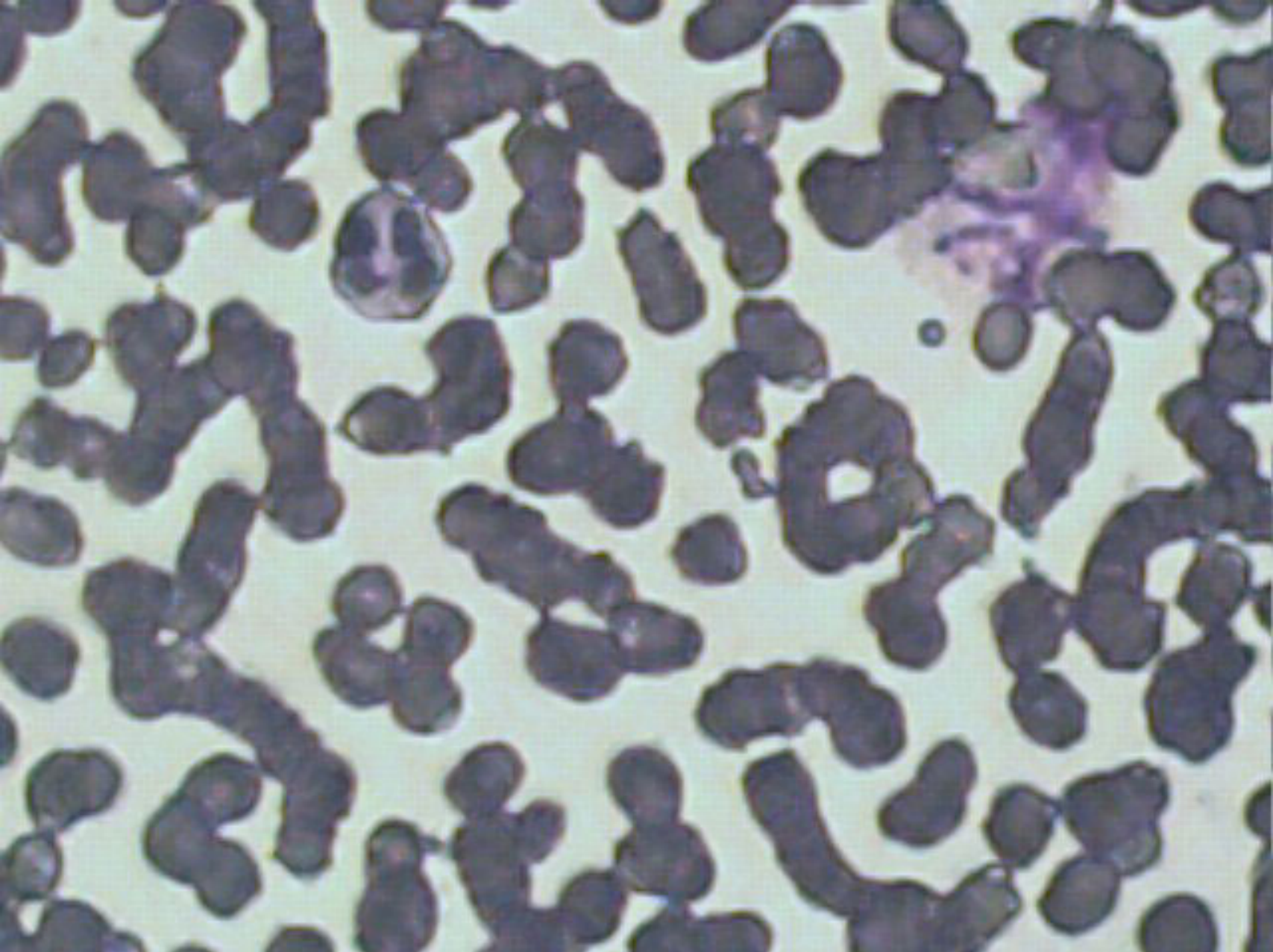
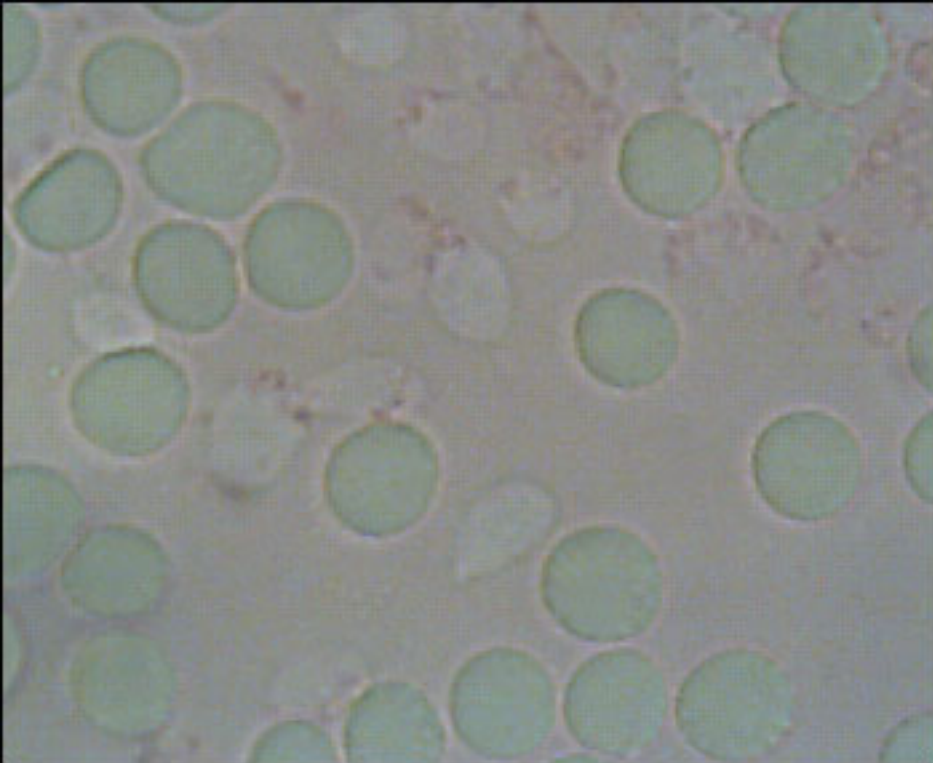


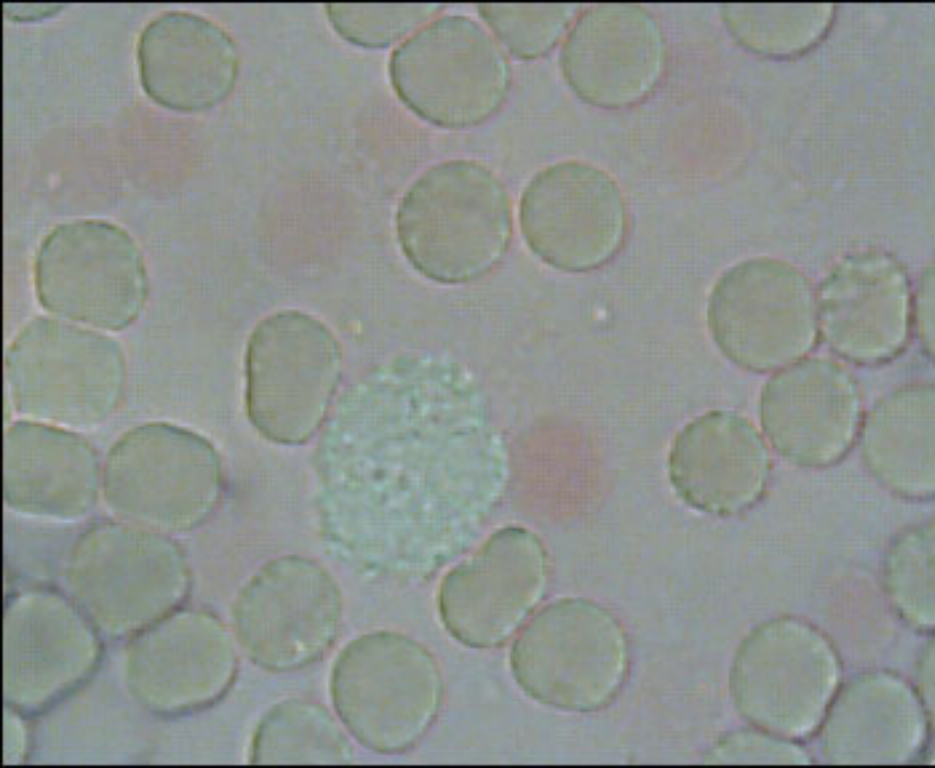I have not seen these particulates at the edges of my RBC's on any other images online and do not appear to be normal and might explain part of the true reason for my failing health

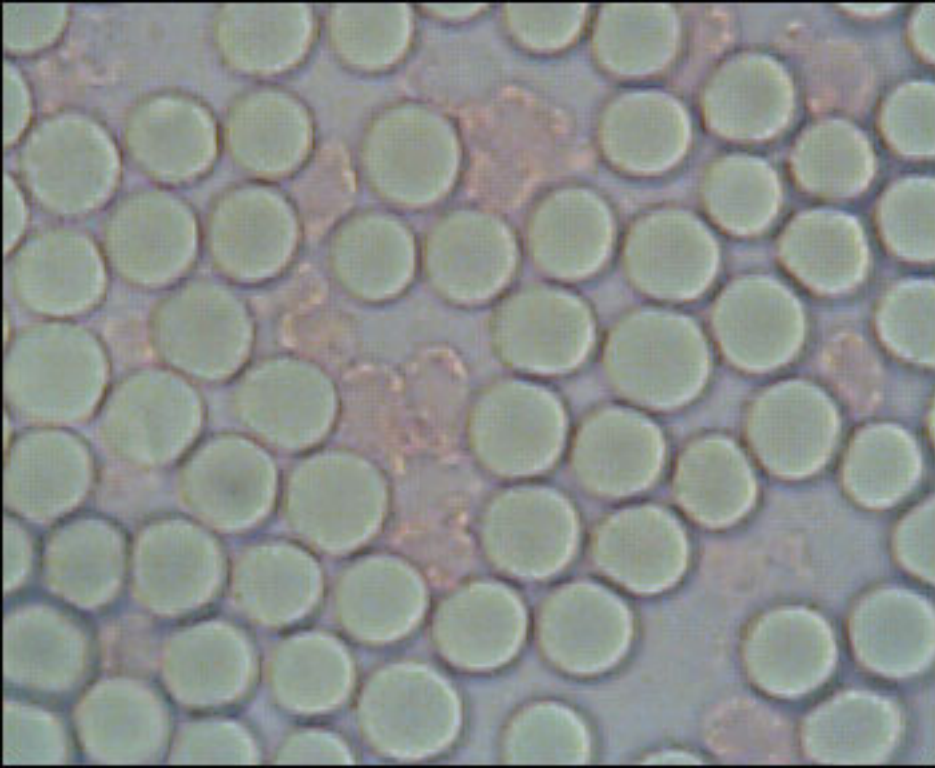


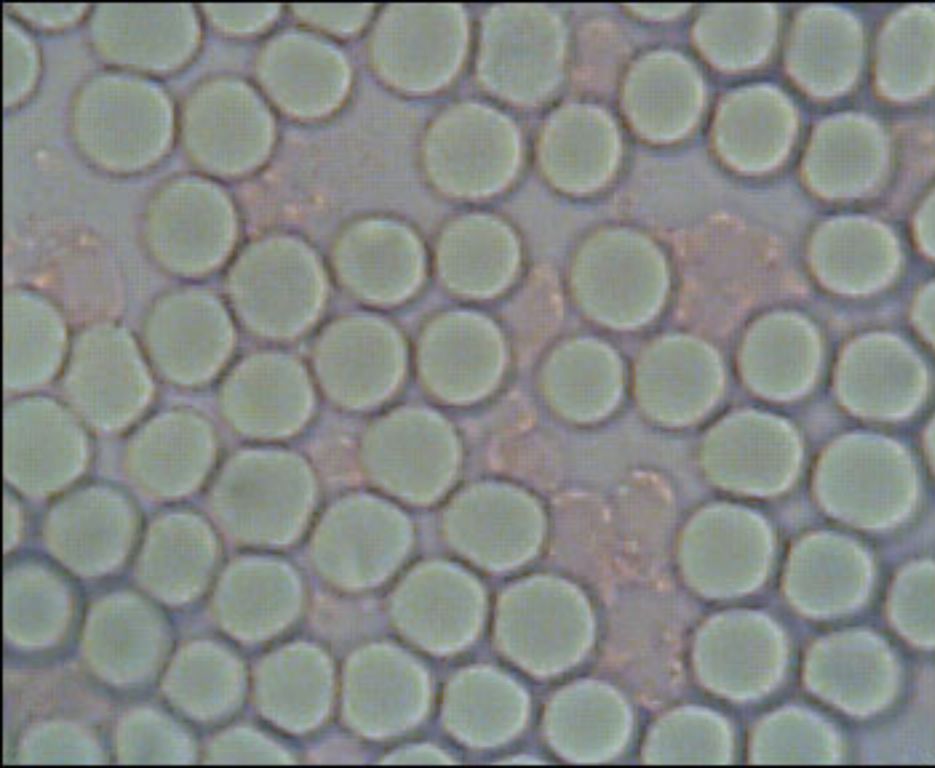
The chain formations of RBC's is known as Rouleaux formation and the abundance of smaller RBCs not typical are spherocytes, these have been associated with the genetic trait being called Wilson's Disease. A Wilson's Disease expert hematologist can tell you that it is highly possible that if someone who has Wilson's was given an incompatible transfusion it could result in hemolysis and trigger a downward spiral in the person's health resulting in a tortuous and agonizing demise.

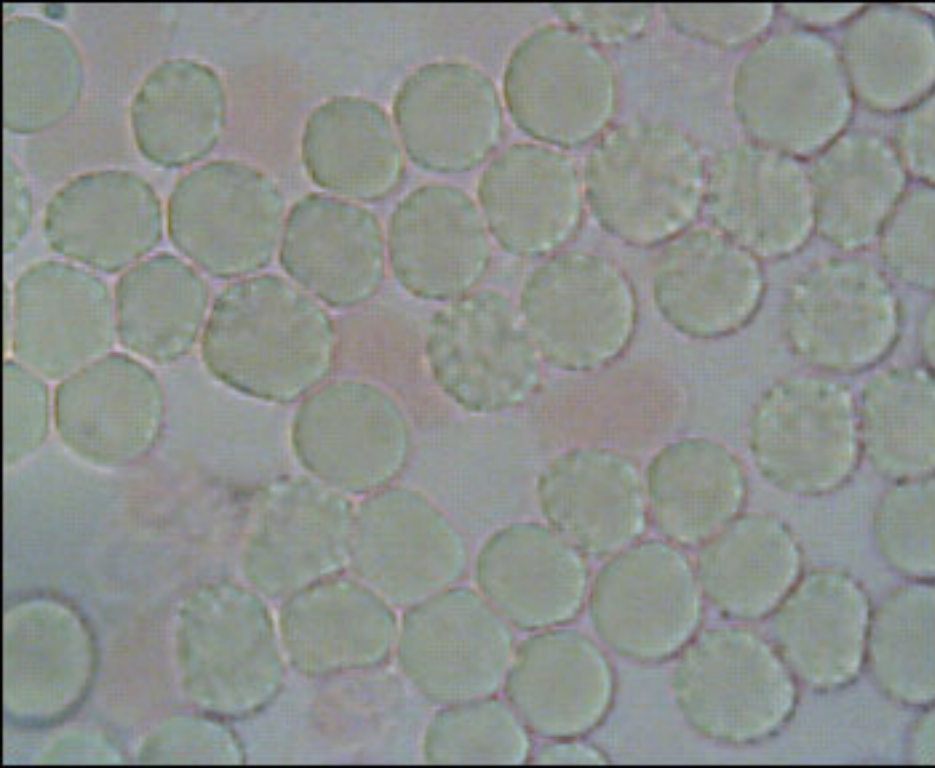


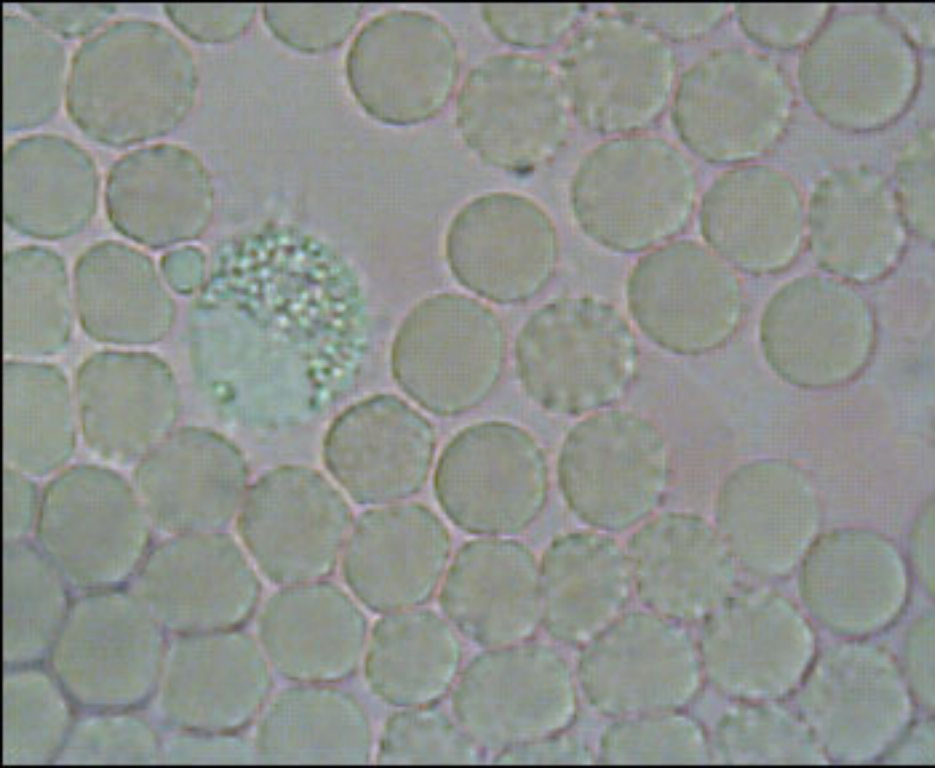The atypical cells barely visible in this image could explain scientifically why I am suffering so greatly and that I am telling the truth, but I have yet to find a hematologist not the irregularities in my RBCseven though one has noted atypical leucocytes.



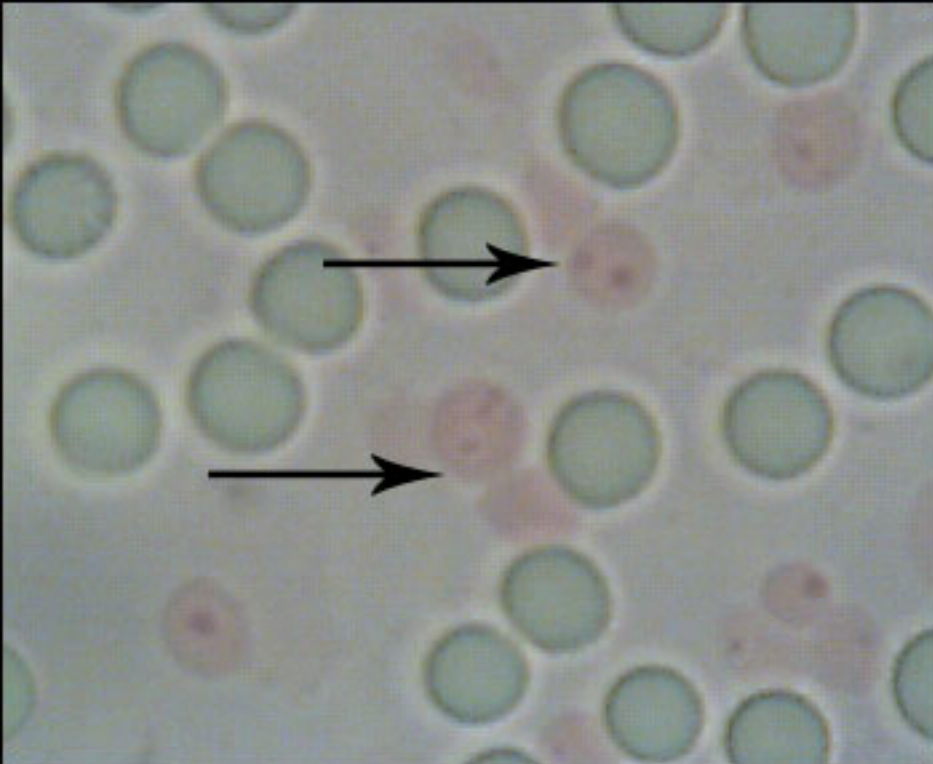












These ghosting reticulocytes are barely visible with eosin stain and don't even seem to appear with Wright's stain. Keep in mind I was given three units of incompatible blood and I've felt like I'm dying very painfully and very slowly ever since. I believe my blood tells the truth.