Yellowing Left Palm

These pin point red dots started appearing all over my upper arms about two months ago in March 2006. Some are bright red, others little deeper beneath skin. Dentist made observation of petechiae in gums. The hygentist showed them to me and I saw them in my lips sporadically ever since.

These yellow spots were three now two and inconsistant with any type of bruising I've ever had before

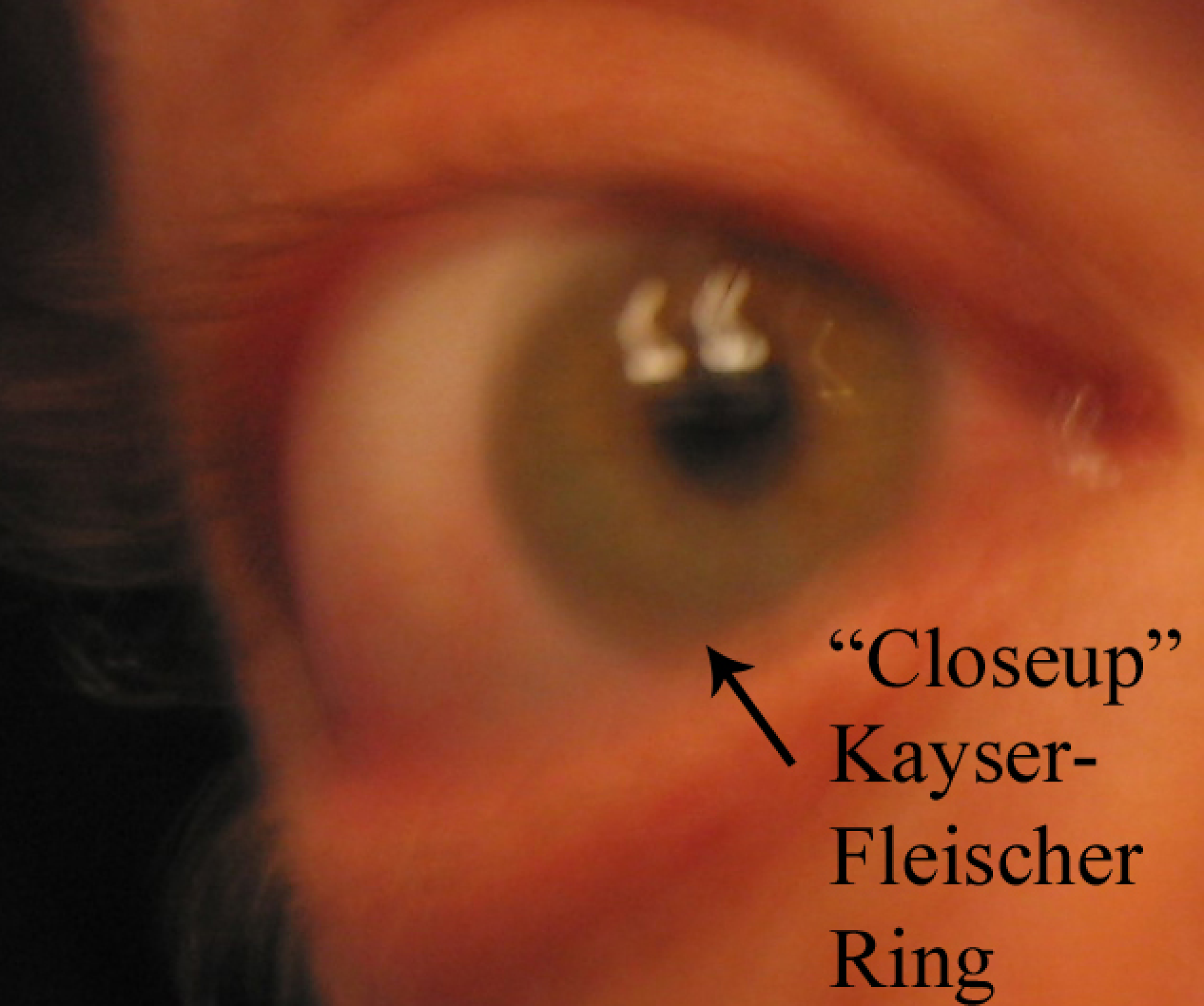
“Closeup”
Kayser-
Fleischer
Ring

Heavier KF pigmentation tends to occur on upper region of cornea

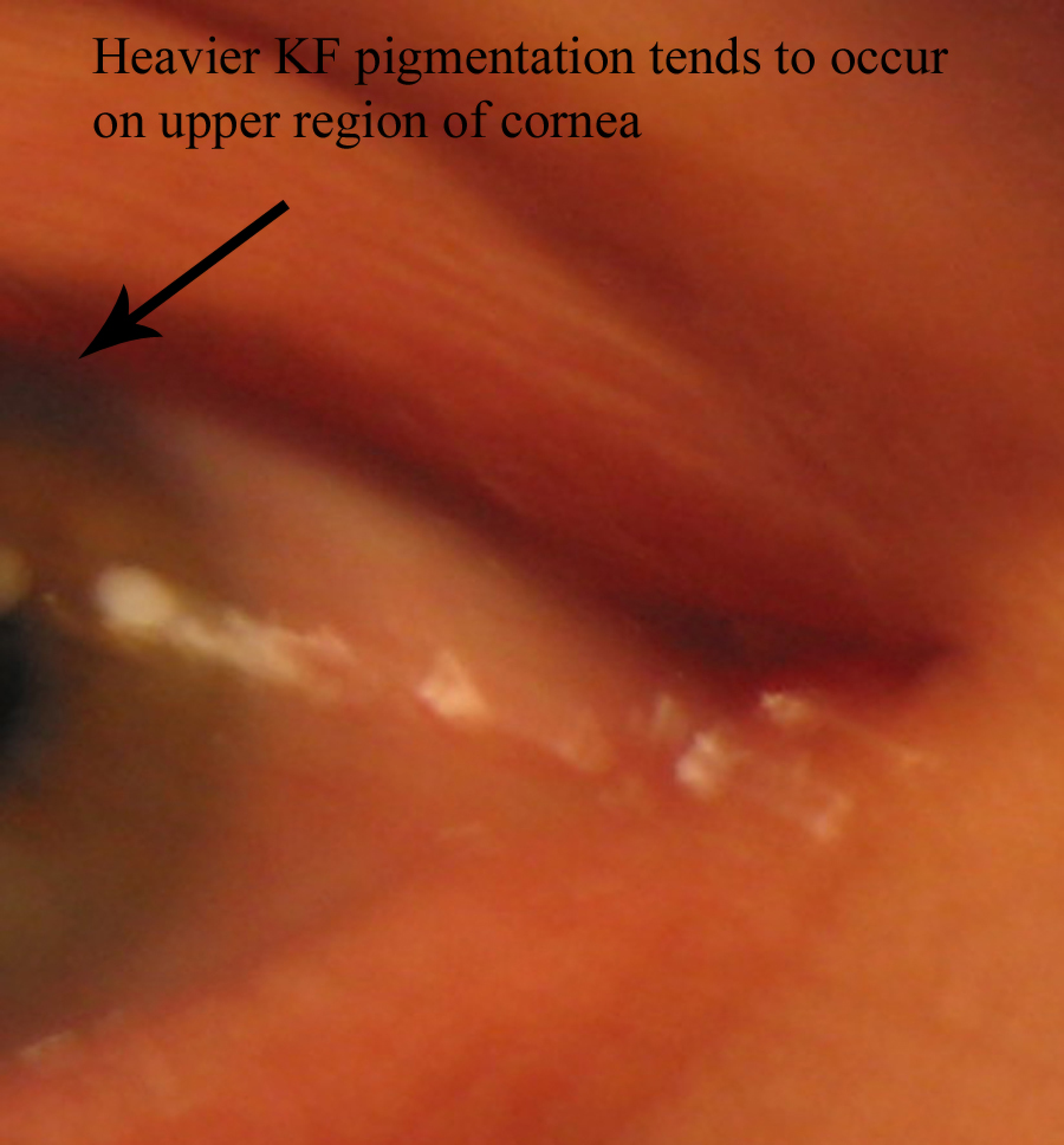

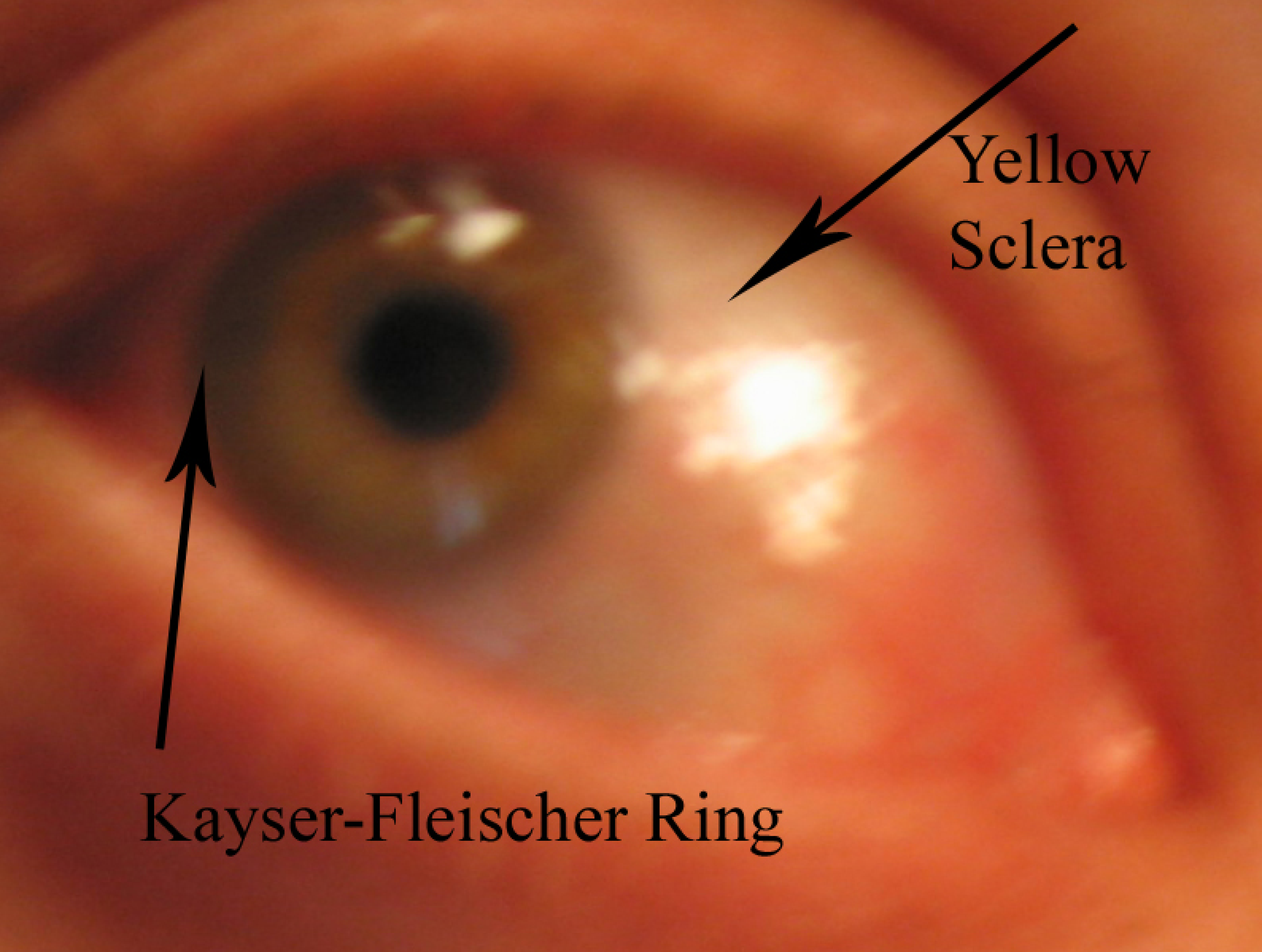
Yellow
Sclera
Kayser-Fleischer Ring


Kayser-Fleischer Ring & Yellow Sclera

With Kayser-Fleischer Rings (Wilson's associated) accumulation tends to be heaviest on upper region of cornea
Yellow Sclera also noted - jaundice symptomatic of hepatic involvment Wilson's Disease